

REVEAL™ 35C
FLAT PANEL DETECTOR

KA
IMAGING™

MXR | **THE IMAGING**
SOLUTIONS COMPANY

**THE FLEXIBILITY
OF A 3-IN-1
SOLUTION**



OUR VISION:
INNOVATIVE X-RAY
EVERYWHERE

REVEAL™ 35C

FLAT PANEL DETECTOR



WELCOME **INNOVATION**
AND EXPLORE **FURTHER**



1 exposure



3 images



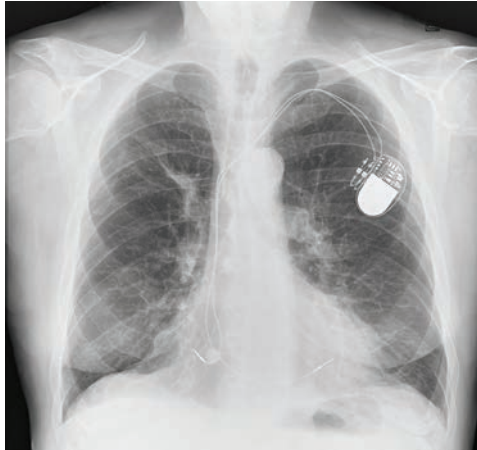
0 motion artifacts

Reveal™ 35C is the first and only mobile dual-energy detector on the market. Thanks to its *Spectra/DR*® technology, this detector overcomes the limitations of other dual-energy technologies. This **3-in-1** solution simultaneously acquires 3 images in 1 single exposure, improving visualization of bone and tissue.

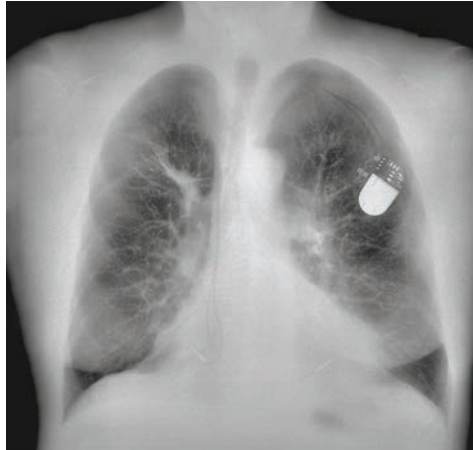
Dual-energy images are clinically proven¹ to enhance the visualization of lung nodules, pneumonia, line and tube tips, pneumothorax, retained surgical objects and more.

A 3-IN-1 SOLUTION

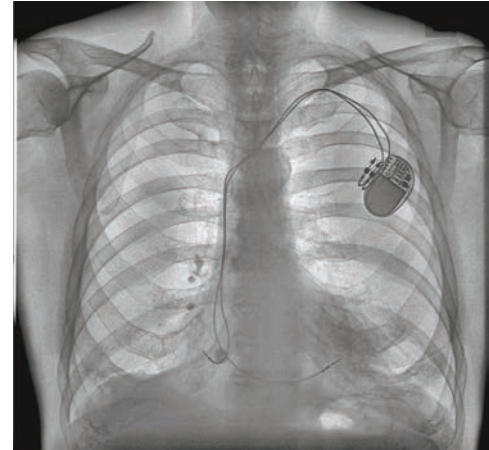
- 3 images in 1 X-ray exposure. Sharp Bone and Tissue images, high-quality DR² with DQE as high as 75%.
- DR, Bone and Tissue images help reveal lung nodules³, pneumonia⁴ (including COVID-19), hidden fractures, line and tube ends, indeterminate nodules^{1,1}, and coronary calcifications^{1,5} with high sensitivity.
- Thanks to *SpectralDR*[®], explore lateral and oblique views with dual energy for the first time to see behind the heart.



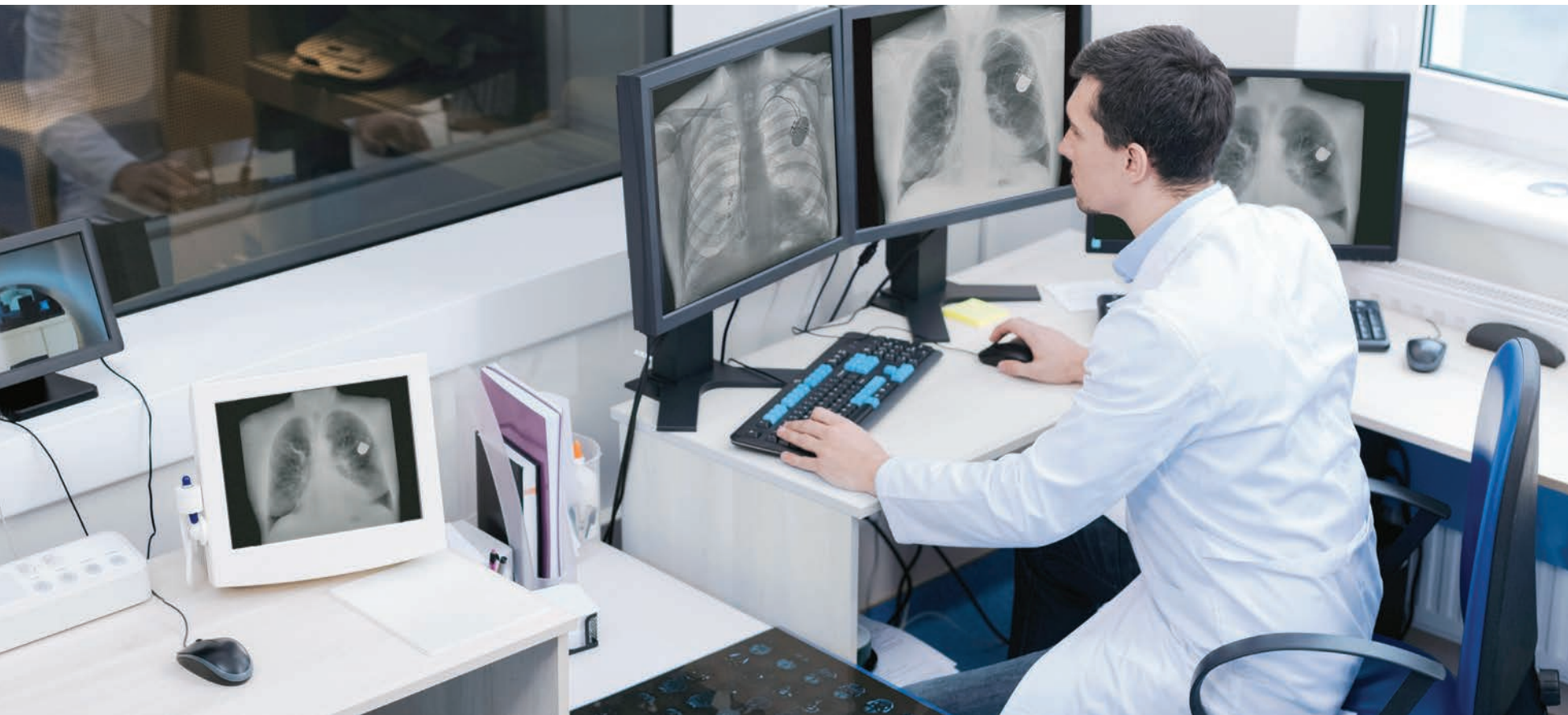TRADITIONAL DR IMAGE



SOFT TISSUE IMAGE



BONE IMAGE

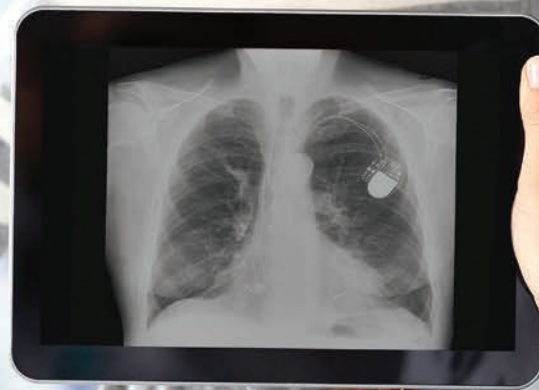


FLEXIBLE APPLICATIONS

- Standard cassette size: 14 X 17 inches (ISO 4090).
- Retrofittable: get DR and spectral images from any X-ray system. No hidden costs.
- Compatible with existing fixed systems.
- Fixed, mobile and portable applications.

PURCHASING OPTIONS TO MEET YOUR **NEEDS**

Choose between capital purchase
or flexible subscription models



BETTER HOSPITAL AND PATIENT **OUTCOMES**



33% more pneumonia cases found
compared to X-ray thanks to dual-energy images⁴



43% more lesion visibility
when dual-energy images were included³



Increased confidence in 57% of ICU cases
thanks to dual-energy images with no added reading
time⁵



Better visibility of lines and tube tips⁵



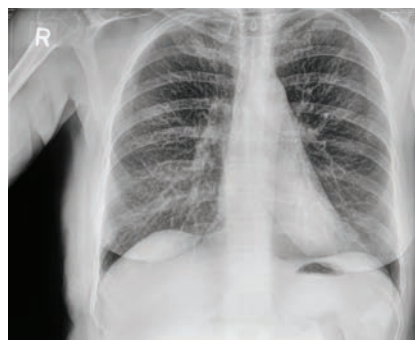Increases revenue through incidental findings;
Protects revenue by reducing outflows

REAL CASES

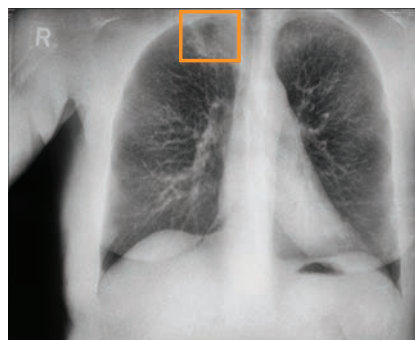
KA Imaging has initiated a clinical trial at Grand River Hospital in Kitchener, Ontario, Canada to image lung cancer patients with Reveal™ 35C to visualize lung nodules and lesions. Preliminary results have shown **43% more lesion visibility**³ when our *Spectra/DR*® images were included.

Hidden Masses Discovered in PA Chest X-ray

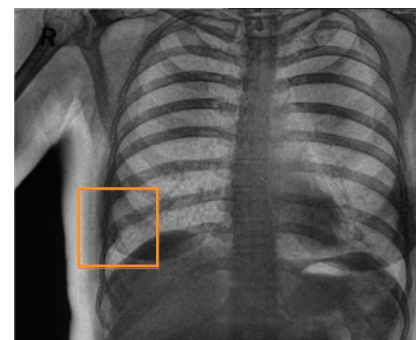
Apical lesion in the right upper lobe was missed in the conventional PA X-ray image but was visible in the soft-tissue dual-energy X-ray image.



TRADITIONAL DR IMAGE



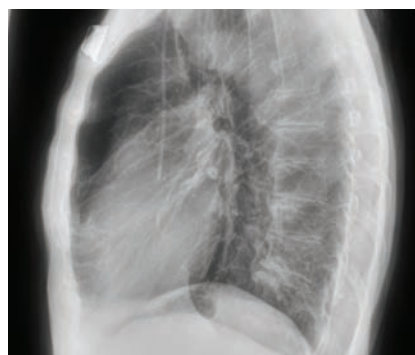SOFT TISSUE IMAGE



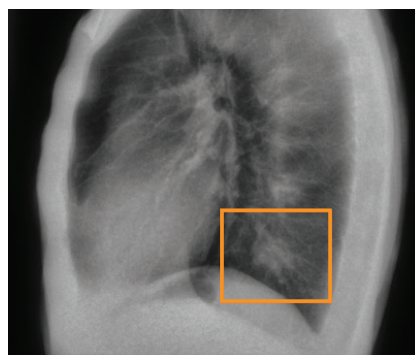
BONE IMAGE

Hidden Masses Discovered in Lateral Chest X-ray

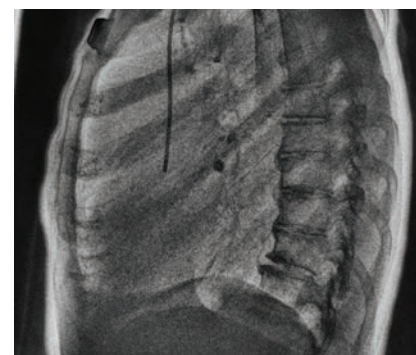
Upon reviewing the soft-tissue and bone dual-energy images, radiologists confirmed a mass in the lower left lobe, a calcified granuloma in the lower right, and a possibility of a new right lower lobe mass.



TRADITIONAL DR IMAGE



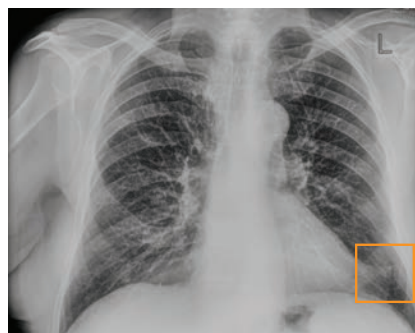SOFT TISSUE IMAGE



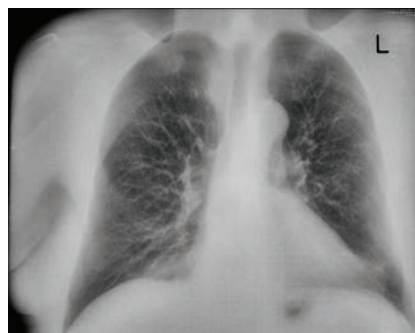
BONE IMAGE

Fractures Discovered in PA Chest X-ray

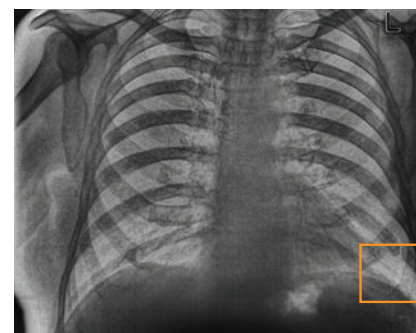
Old fractures missed on the PA image is significantly visible in the bone dual energy X-ray image.



TRADITIONAL DR IMAGE



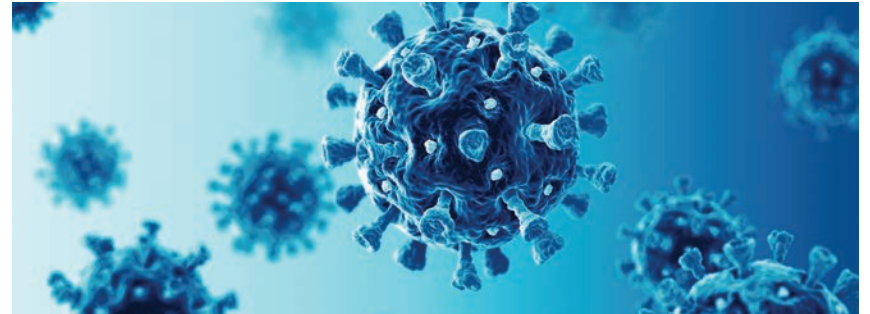
SOFT TISSUE IMAGE



BONE IMAGE

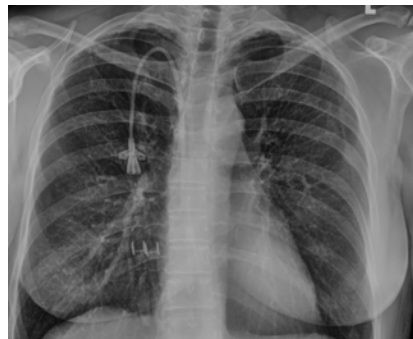COVID-19

KA Imaging has also partnered with a team of researchers from Toronto for the early detection of COVID-19. In the study *Spectra/DR*[®] Dual-energy Radiographs and Thoracic Tomograms were compared to CT scans, which is currently the standard of care for confirming pneumonia. Preliminary results have shown that **33% more pneumonia cases**⁴ were identified thanks to KA Imaging's Reveal 35C detector with *Spectra/DR*[®] technology than with conventional digital radiography.

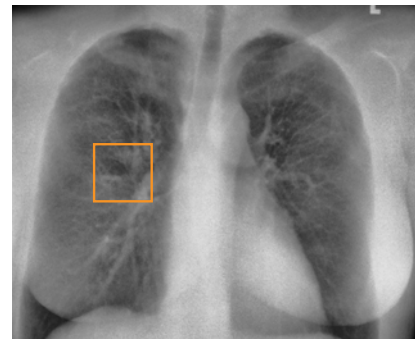


Hidden focal opacity

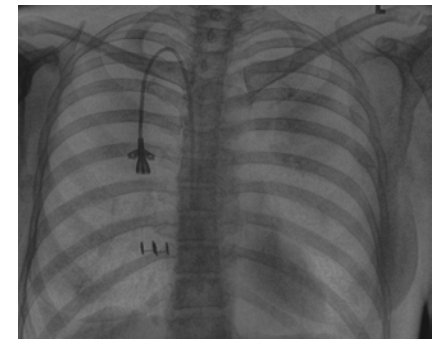
In this study, the conventional DR was read as normal. Upon viewing the Dual-Energy Soft Tissue image, the radiologist noticed a highlighted focal opacity indicative of pneumonia (confirmed on CT).



TRADITIONAL DR IMAGE



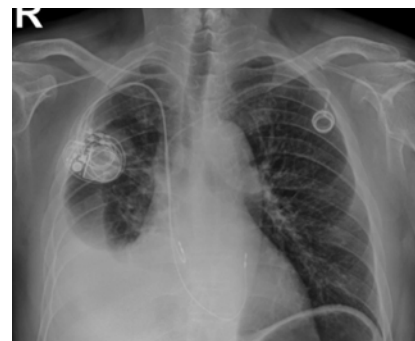SOFT TISSUE IMAGE



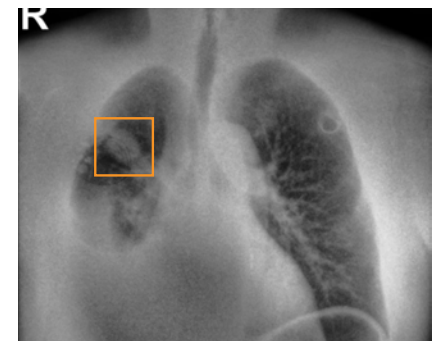BONE IMAGE

Mass overlapping in-dwelling device

In this study, the dual energy soft tissue image revealed a suspicious soft tissue mass. In this case, the mass was overlapping the in-dwelling device (pacemaker).



TRADITIONAL DR IMAGE



SOFT TISSUE IMAGE



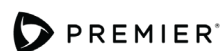Available for sale in Australia, Canada, the United States, New Zealand, Taiwan, Indonesia, United Kingdom, Vietnam, and in the European Union.

Contact us for availability in other countries.

REFERENCES

1. Improved patient outcomes

- 1.1 (Lung Nodules) Oda, Seitaro, Kazuo Awai, Yoshinori Funama, Daisuke Utsunomiya, Yumi Yanaga, Koichi Kawanaka, Takeshi Nakaura et al. "Detection of small pulmonary nodules on chest radiographs: efficacy of dual-energy subtraction technique using flat-panel detector chest radiography." *Clinical radiology* 65, no. 8 (2010): 609-615.
 - 1.2 (Pneumothorax) Urbaneja, A., Dodin, G., Hoosu, G., et al. (2018) *Added Value of Bone Subtraction in Dual-energy Digital Radiography in the Detection of Pneumothorax: Impact of Reader Expertise and Medical Specialty*. The Association of University Radiologists. Elsevier Inc.
 - 1.3 (Pneumonia) Martini, Katharina, Marco Baessler, Stephan Baumueller, and Thomas Frauenfelder. "Diagnostic accuracy and added value of dual-energy subtraction radiography compared to standard conventional radiography using computed tomography as standard of reference." *PloS one* 12, no. 3 (2017): e0174285.
 - 1.4 (Tuberculosis) Sharma, Madhurima, Manavjit Singh Sandhu, Ujjwal Gors, Dheeraj Gupta, and Niranjana Khandelwal. "Role of digital tomosynthesis and dual energy subtraction digital radiography in detection of parenchymal lesions in active pulmonary tuberculosis." *European Journal of Radiology* 84, no. 9 (2015): 1820-1827.
 - 1.5 (Coronary Calcifications) Song, Yingnan, Hao Wu, Di Wen, Bo Zhu, Philipp Graner, Leslie Ciancibello, Haran Rajeswaran et al. "Detection of coronary calcifications with dual energy chest X-rays: clinical evaluation." *The International Journal of Cardiovascular Imaging* (2020): 1-8.
2. Maurino, S. L., Badano, A., Cunningham, I. A., & Karim, K. S. (2016, March). Theoretical and Monte Carlo optimization of a stacked three-layer flat-panel x-ray imager for applications in multi-spectral diagnostic medical imaging. In *Medical Imaging 2016: Physics of Medical Imaging* (Vol. 9783, p. 97833Z). International Society for Optics and Photonics.
 3. S. L. Maurino, K. S. Karim, V. Venkatesh. Diagnostic value of single-exposure dual-energy subtraction radiography in lung lesion detection: initial results. *European Congress of Radiology-ECR 2022, 2022*.
 4. Sanchez F, Kandel S, May M, Ronghe S, Rogalla P. Diagnostic value of dual-energy chest x-ray in immunocompromised patients to rule out pneumonia: initial results. *European Congress of Radiology-ECR 2021, 2021*.
 5. Rogalla P, Karim K. Added diagnostic value of portable dual-energy chest X-ray in a non-radiological reviewing environment. *Radiological Society of North America- RSNA 2022, 2022*
 6. Kuhlman, Janet E., Jannette Collins, Gregory N. Brooks, Donald R. Yandow, and Lynn S. Broderick. "Dual-energy subtraction chest radiography: what to look for beyond calcified nodules." *Radiographics* 26, no. 1 (2006): 79-92.
 7. Manji, Farheen, Jiheng Wang, Geoff Norman, Zhou Wang, and David Koff. "Comparison of dual energy subtraction chest radiography and traditional chest X-rays in the detection of pulmonary nodules." *Quantitative imaging in medicine and surgery* 6, no. 1 (2016): 1.
 8. Karim S Karim, "Single Exposure, Digital Dual-Energy Subtraction X-Ray Ushers in a New Era of Diagnostic X-Ray Imaging," *Radiology Management*, Mar/Apr 2021.



Contracted Supplier PP-IM-434

Manufacturer:

KA Imaging Inc.
3-560 Parkside Dr
Waterloo, ON
Telephone: 1-226-215-9897

Sales and Product Information

sales@kaimaging.com

Customer Support

support@kaimaging.com

Investor Information

investor@kaimaging.com

Media Inquiries

media@kaimaging.com



QualRep Services B.V.

Utrechtseweg 310 - Bldg B42, NL-6812 AR Arnhem, The Netherlands

